

Large Multicystic Dysplastic Kidney Mimicking a Large Cystic Renal Neoplasm

PRIYANK YADAV¹, SANJOY KUMAR SUREKA², M S ANSARI³, RAHUL SONI⁴, HIRA LAL⁵

ABSTRACT

Multicystic Dysplastic Kidney (MCDK) is one of the most common renal conditions seen in paediatric population. The natural history typically involves involution and many of the patients with unilateral disease may actually never become symptomatic. The initial evaluation is usually done on Ultrasonography (USG) while cross-sectional imaging and nuclear scan are reserved for diagnostic dilemmas. Management is conservative and surgery is done for selected patients with symptomatic cysts or suspicion of neoplasm. We present an interesting case of MCDK in a nine-month-old female hypertensive child presenting with a large abdominal mass increasing in size with imaging features similar to cystic neoplasm and managed with nephrectomy.

Keywords: Nephrectomy, Renal dysplasia, Wilm's tumour

CASE REPORT

A nine-month-old female was referred to us for incidentally detected left sided abdominal lump. Ultrasonography (USG) at that time was suggestive of well circumscribed, encapsulated multicystic left renal mass. On evaluation, she was found to be hypertensive (blood pressure=108/82 mmHg) and was started on amlodipine (1.25 mg once daily). There was no history of haematuria or recurrent urinary tract infection. For characterization of the renal mass, Contrast Enhanced Computed Tomography (CECT) abdomen was done which revealed an 8.5 x 7.5 x 7.0 cm multiseptate cystic mass occupying the mid and lower pole of left kidney (BOSNIAK GRADE 3) [1] displacing the pancreatic and splenic vessels but with maintained fat planes [Table/Fig-1]. The child was advised corecut biopsy of the mass but was lost to follow up. She again presented at the age of two years with increase in the size of lump, CECT abdomen revealed a 14.8 x 12.3 x 11.3 cm well defined multiloculated cystic lesion replacing the left kidney with mild enhancement of the walls and foci of calcification within [Table/Fig-2]. She underwent USG guided corecut biopsy which was reported as inconclusive. With a high suspicion of Wilm's tumour, as per International Society of Paediatric Oncology (SIOP) protocol [2], she received vincristine (0.05 mg/kg) and dactinomycin (0.045 mg/kg/dose) based chemotherapy.

At the end of four cycles, the lesion did not regress in size and the patient was subsequently taken up for left open radical nephrectomy. Intraoperatively, a well encapsulated mass was found replacing the entire left kidney with no invasion of adjacent organs or renal vein thrombus. No significant retroperitoneal lymph nodes were found. The histopathology report showed numerous dilated non-communicating cysts of variable sizes, lined by low cuboidal to

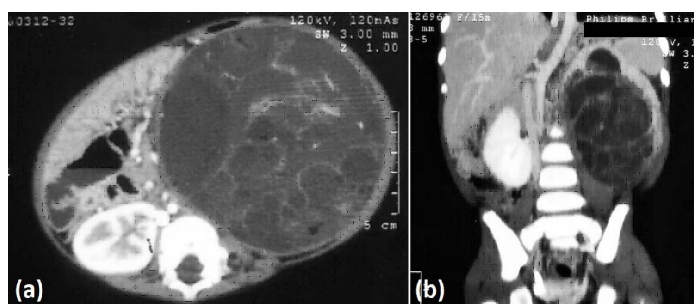
flattened lining epithelium present throughout the cortex and medulla with focal areas showing primitive duct lined by undifferentiated cells and surrounded by fibromuscular collars suggestive of MCDK [Table/Fig-3]. No normal renal parenchyma was seen. Postoperative period was uneventful. Blood pressure normalized within 24 hours and she was discharged on fifth postoperative day. The child is asymptomatic and normotensive at one year of follow up.

DISCUSSION

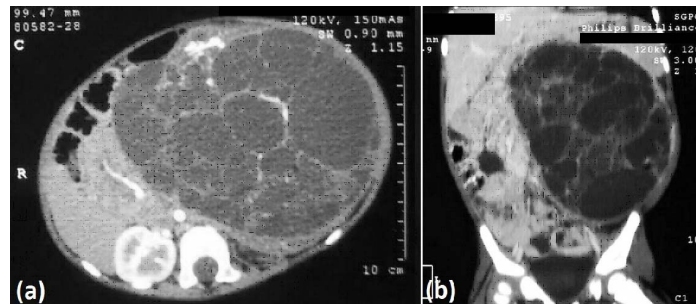
MCDK is a common cause of abdominal mass in neonates, second only to a hydronephrotic kidney. The opposite kidney is the only functioning renal parenchyma and usually undergoes compensatory hypertrophy [3]. Bilateral involvement is incompatible with life. Most of the cases are diagnosed on prenatal ultrasonography and typically reveal multiple non-communicating cysts with little or no parenchyma.

The natural history of MCDK shows total or partial involution in over 90% of the cases. The rate of involution is variable, the mean rate being around 1.0 cm/year. It is most rapid in the first 30 months of age and decreases thereafter. A higher rate of involution is reported for kidneys that involute completely [4]. Few reports are present regarding increase in the size of dysplastic kidneys post-natally [5,6].

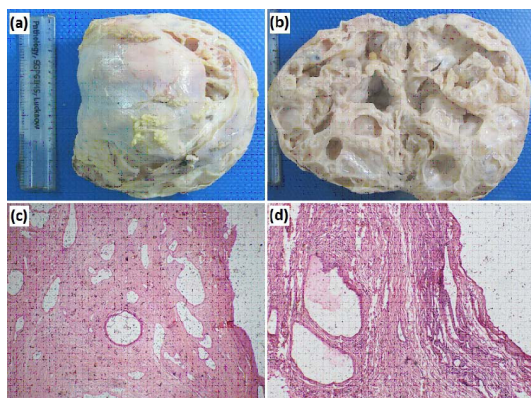
The preferred initial investigation for imaging of MCDK is ultrasonography which typically shows multiple non-communicating cysts of variable size with little or no parenchyma. In case of large masses where the possibility of a neoplastic mass may be real, CECT is useful. As the MCDK has no normal renal tissue, it has a different nephrographic appearance from the normal renal parenchyma on



[Table/Fig-1]: (a) Axial and (b) coronal CECT abdomen at nine months of age showing huge well defined multiloculated cystic lesion with enhancing septae replacing most of the left kidney (BOSNIAK GRADE 3).



[Table/Fig-2]: (a) Axial and (b) coronal CECT abdomen at two years of age showing increase in the size of multiloculated cystic lesion replacing the left kidney with mild enhancement of the walls (BOSNIAK GRADE 3).



[Table/Fig-3]: (a) Left radical nephrectomy specimen showing a smooth, greyish white and partially lobulated outer surface. (b) Cut surface of the specimen showing multiple cysts filled with clear fluid. Cortico-medullary differentiation cannot be made microscopy (H&E stain) at (c) 4X and (d) 10X magnification showing numerous dilated non-communicating cysts of variable sizes, lined by low cuboidal to flattened lining epithelium present throughout the cortex and medulla. Focal areas show primitive duct lined by undifferentiated cells and surrounded by fibromuscular collars.

CECT. Many cases will not have a definitive renal cortex; those which do have some parenchyma will typically have a central core of dysplastic tissue with peripherally arranged cysts [7]. Cases with little or no renal parenchyma are usually reported as Bosniak 2 or 3 lesions and are difficult to differentiate from other renal conditions such as a grossly hydronephrotic kidney, benign multilocular cyst, localized renal cystic disease, cystic Wilm's tumour or even cystic renal cell carcinoma.

Nuclear imaging has been traditionally used to differentiate MCDK from large hydronephrotic kidney. DMSA scan is particularly helpful since DMSA is a cortical agent and thus binds to the normal residual renal cortex. In case of hydronephrotic kidney, localized renal cystic disease and cystic Wilm's tumour or RCC, a DMSA scan will reveal some function as the remaining parenchyma is normal but MCDK will not show any uptake [8].

The incidence of hypertension in MCDK is low. In a review by Narchi H, the mean probability of hypertension in case of unilateral MCDK was found to be 5.4 per 1000 [9]. While the cause of hypertension is still debated, one of the suggested mechanisms is ischaemia induced renin secretion from the juxtaglomerular apparatus of mature glomeruli and interlobular arteries present in the scarred areas of the dysplastic kidney [10]. This is however, doubted by others who believe that hypertension is secondary to the pronounced ectopic renin expression by macrophages [11]. After nephrectomy, hypertension has been seen to improve [12]. The mechanism and pathophysiology of this effect is also unknown. In our case as well, the patient became normotensive after surgery.

The management of MCDK is primarily conservative. The indications of surgery have been reported as abdominal or flank pain, recurrent urinary tract infection, suspicion of malignancy and progressively increasing size of the kidney. Nephrectomy allows an accurate final histopathological diagnosis and may be necessary in situations where Wilm's tumour or RCC cannot be ruled out. Recent reports

have doubted the role of conservative management of MCDK. Perez LM et al., suggest that early nephrectomy is more cost effective than observation in neonates with MCDK [13]. This study compared the two modalities longitudinally in terms of cost effectiveness. As per the revised Canadian Urology Association guidelines, MCDK can be classified as simple or complex. "Simple" refers to unilateral dysplasia with a normal contralateral kidney with compensatory hypertrophy and no associated genitourinary anomalies detected by USG or physical examination. In case of a simple MCDK, follow up is not indicated beyond 24 months. This may better define the patients requiring abbreviated follow up compared to those that must be either operated early or followed up longer [14].

CONCLUSION

MCDK is the most common renal cystic disease in the newborn. Most cases are detected during fetal ultrasonography. Although it usually regresses with age, few patients may have a renal mass that increases in size. Differentiation of such large MCDK masses from malignancy is important yet difficult and requires a combination of radiological and histopathological evaluation. The treatment of such masses is nephrectomy which also provides histological confirmation.

REFERENCES

- [1] Warren KS, McFarlane J. The Bosniak classification of renal cystic masses. *BJU Int.* 2005;95(7):939-42.
- [2] Reinhard H, Semler O, Bürger D, Bode U, Flentje M, Göbel U, et al. Results of the SIOP 93-01/GPOH trial and study for the treatment of patients with unilateral nonmetastatic Wilms Tumour. *Klin Padiatr.* 2004;216(3):132-40.
- [3] Pope J. Renal dysgenesis and cystic disease of the kidney. In: Wein A, Kavoussi L, Novick A, Partin A, Peters C, editors. *Campbell's urology*, 10th edn. Philadelphia: Saunders; 2012. Pp. 3161-96.
- [4] Siqueirarabelo EA, Oliveira EA, Silva JM, Oliveira DS, Colosimo EA. Ultrasound progression of prenatally detected multicystic dysplastic kidney. *Urology.* 2006;68(5):1098-102.
- [5] Vinocur L, Slovis TL, Perlmutter AD, Watts FB, Chang CH. Follow-up studies of multicystic dysplastic kidneys. *Radiology.* 1988;167(2):311-15.
- [6] White R, Greenfield SP, Wan J, Feld L. Renal growth characteristics in children born with multicystic dysplastic kidneys. *Urology.* 1998;52(5):874-77.
- [7] Levine E, Grantham JJ. Radiology of cystic kidneys. In: Gardner KD JR, Bernstein J, editors. *The cystic kidney*, Dordrecht, The Netherlands: Kluwer Academic Publishers; 1990. Pp. 171-206.
- [8] Sarhan OM, Alghanbar M, Alsulaimi A, Alharbi B, Alotay A, Nakshabandi Z. Multicystic dysplastic kidney: Impact of imaging modality selection on the initial management and prognosis. *J Pediatr Urol.* 2014;10(4):645-49.
- [9] Narchi H. Risk of hypertension with multicystic kidney disease: a systematic review. *Arch Dis Child.* 2005;90(9):921-24.
- [10] Konda R, Sato H, Ito S, Sakai K, Kimura N, Nagura H. Renin containing cells are present predominantly in scarred areas but not in dysplastic regions in multicystic dysplastic kidney. *J Urol.* 2001;166:1910-14.
- [11] Liapis H, Doshi RH, Watson MA, Liapis A, Steinhardt GF. Reduced renin expression and altered gene transcript profiles in multicystic dysplastic kidneys. *J Urol.* 2002;168:1816-20.
- [12] Abdulhannan P, Stahlschmidt J, Subramaniam R. Multicystic dysplastic kidney disease and hypertension: clinical and pathological correlation. *J Pediatr Urol.* 2011;7(5):566-68.
- [13] Pérez LM, Naidu SI, Joseph DB. Outcome and cost analysis of operative versus nonoperative management of neonatal multicystic dysplastic kidneys. *J Urol.* 1998;160(3 Pt 2):1207-11.
- [14] Psocoy K. Multicystic Dysplastic Kidney (MCDK) in the neonate: The role of the urologist. *Can Urol Assoc J.* 2016;10(1-2):18-24.

PARTICULARS OF CONTRIBUTORS:

1. Senior Resident, Department of Urology, Sanjay Gandhi Post Graduate Institute of Medical Sciences, Lucknow, Uttar Pradesh, India.
2. Assistant Professor, Department of Urology, Sanjay Gandhi Post Graduate Institute of Medical Sciences, Lucknow, Uttar Pradesh, India.
3. Professor, Department of Urology, Sanjay Gandhi Post Graduate Institute of Medical Sciences, Lucknow, Uttar Pradesh, India.
4. Senior Resident, Department of Urology, Sanjay Gandhi Post Graduate Institute of Medical Sciences, Lucknow, Uttar Pradesh, India.
5. Additional Professor, Department of Radiology, Sanjay Gandhi Post Graduate Institute of Medical Sciences, Lucknow, Uttar Pradesh, India.

NAME, ADDRESS, E-MAIL ID OF THE CORRESPONDING AUTHOR:

Dr. Hira Lal,
Additional Professor, Department of Radiology, Room No. 35,
Sanjay Gandhi Post Graduate Institute of Medical Sciences, Raibareilly Road, Lucknow-226014, Uttar Pradesh, India.
E-mail: dhiralal2007@yahoo.co.in

Date of Submission: **Sep 17, 2016**

Date of Peer Review: **Dec 17, 2016**

Date of Acceptance: **Mar 09, 2017**

Date of Publishing: **May 01, 2017**

FINANCIAL OR OTHER COMPETING INTERESTS: None.